

CASE REPORT

Hepatic Papillary Process - An Anatomic Variant of Liver

Ghanshyam Dev, Rashmi Sharma, Bhawna Sharma

Abstract

Hepatic Papillary process is an anatomic variant of liver. When large can simulate mass lesion in pancreatic head region or periportal lymphnode on imaging however liver tissue characteristics and continuity of the process with the caudate lobe facilitate the differentiation between extrahepatic portocaval mass and papillary process. CT is the modality of choice for the right diagnosis of liver anatomical variants.

Key Words

Hepatic Papillary process, Hemangioma, Ultrasonography, CT scan, Caudate lobe, Anatomic Variant

Introduction

Hepatic Papillary process is an anatomic variant of liver. When large can simulate mass lesion in pancreatic head region or periportal lymphnode on imaging however liver tissue characteristics and continuity of the process with the caudate lobe facilitate the differentiation between extrahepatic portocaval mass and papillary process. (1) CT is the modality of choice for the right diagnosis of liver anatomical variants.

Case Report

A 48 years female was admitted in the medicine department of our hospital with complaints of fever and pain lower abdomen associated with nausea and burning micturition. She was known hypertensive as well as diabetic for last 5 years and had undergone cholecystectomy for gall bladder calculi.

On clinical examination she was febrile and pale and had hepatosplenomegaly. Her BP was 136/96 mm of Hg. On investigating her HB was 5.3 gm%, RFT's were normal, SGOT and SGPT were also normal, however alkaline phosphatase and Gamma-Glutamyl transferase were raised. Her serum Alpha- fetoprotein was 6.881 ngm/ml and blood sugar (F) was 225 mg/dl.

On ultrasonography, liver was enlarged, 17 cm in size

and shows fatty echotexture. A 17x11 mm sized hyperechoic mass lesion was seen left lobe of liver. A large periportal lymphnode was also seen. Spleen was enlarged, 15 cm in size and portal vein was 16 mm in caliber.

Then CECT Abdomen was done in our department for evaluation of Hepatic mass lesion. CECT revealed Hypodense lesion of size 1.7x1.0 cm in left lobe of liver which show centripetal filling of contrast, so diagnosed as Hemangioma.

No periportal lymphnodes were enlarged, however a tongue like process with attenuation of hepatic tissue was seen arising from caudate lobe of liver extending into portocaval area and more towards left anterior to abdominal aorta measuring approximately 4.6x1.2 cm in size. This was Hepatic Papillary process, a rare anatomical variant of liver, spleen was 15 cm in size and portal vein was 17mm in caliber. So we made the diagnosis of Hemangioma left lobe of liver with Hepatic Papillary process and Hepatosplenomegaly.

A significant number of normal anatomical and Hepatic Vascular variants occur and knowledge of the common variants is essential for diagnosis. Common normal hepatic

From the Department of Radiodiagnosis, Govt Medical College Jammu J&K- India

Correspondence to : Dr. Ghanshyam Dev, Prof. and HOD Radiodiagnosis, Govt. Medical College, Jammu J&K-India 180001

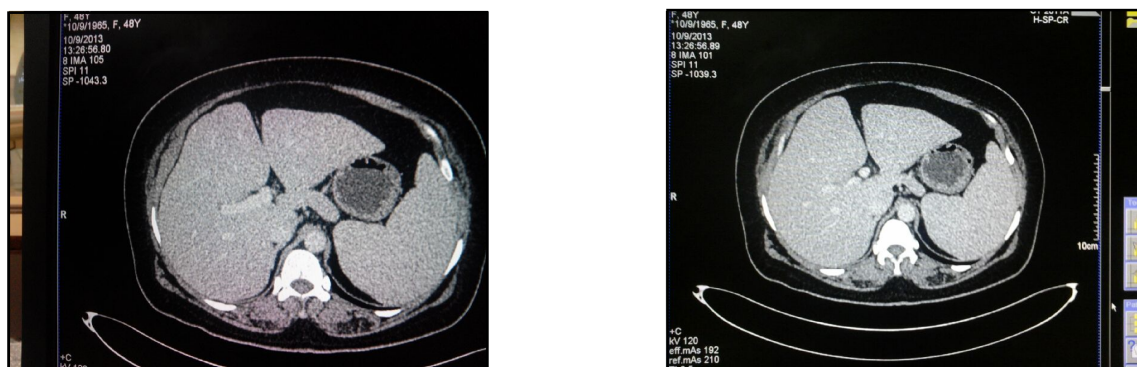


Fig 1&2 Showing Hepatic Papillary Process Anterior to Abdominal Aorta

anatomical variants are-

1. Horizontal elongation of the lateral segment of left lobe of liver.
2. Vertical elongation of right lobe termed Riedel's lobe
3. a prominent caudate lobe process termed Hepatic Papillary process. (1)

The caudate lobe of the liver is divided inferiorly into a lateral caudate process and a medial papillary process. Below the porta hepatis, the papillary process may appear separate from the liver on transverse sectional images. (2) Hepatic Papillary process is elongation of this medial process of caudate lobe which is a small elevation of the hepatic substance extending obliquely lateralwards from the lower extremity of the caudate lobe to the undersurface of the right lobe. It is situated posterior to the porta and separates the fossa of gall bladder from commencement of the fossa for inferior vena cava. (3)

The sonographic appearance of papillary process separated from the caudate process of liver by a fissure is reported. In 2 out of 5 patients with this anatomical variant mimicked a mass lesion. The echogenicity of papillary process is identical to liver parenchyma and knowledge of this variant may help to avoid errors in diagnosis identical to liver parenchyma and knowledge of this variant may help to avoid errors in diagnosis. (4)

Although CT is the modality of choice for evaluation of hepatic morphology still the papillary process may be confused with the extrahepatic lesion on CT examination if its sectional anatomy is not understood because it can appear separate from the liver on at least one CT section in 20% of the patients. It is possible, for example, to mistake a normal papillary process for enlarged porta hepatis lymph node on CT, especially if it appears more lucent than adjacent liver, owing to the partial volume

effect. The probability of misinterpretation on CT increases if the papillary process is involved by focal disease or is diffusely enlarged. Correct identification of the papillary process can be made in most cases ascertaining that its contour conforms to those of caudate lobe on consecutive sections. CT images reformatted in coronal and sagittal planes can confirm the continuity of papillary process with the more superior part of the caudate lobe so, helps in diagnosis. (5)

In conclusion, the papillary process is a potential source of pitfalls in CT interpretation at and just below the porta hepatis. These errors can be avoided by establishing its presence and continuity with the caudate lobe on contiguous axial sections and MPR images. So we here present a case having this rare anatomic variant termed Hepatic Papillary Process.

References

1. Hagga JR. CT&MRI of the whole body, 5th edition, 2009.pp. 1457-58.
2. Kazam E, Whalen JP. Sectional topographic anatomy with CT-Ultrasound correlation. IN: Margulis AR, Burhenne HJ eds. Alimentary tract radiology Vol 3. St.Louis: Mosby, 1979.pp.72-122.
3. Williams PL, Warwick R, eds. Gray's anatomy, 20th edition, Splanchnology Chapter No-XI, .pp.1192.
4. Korn MA . Papillary process of the caudate lobe-erroneous sonography interpretation as space occupying lesion. *Utraschall Med* 1991; 12(4):197-200.
5. Auh YH, Rosen A, Rubenstein WA . CT of the Papillary process of the caudate lobe of the liver. *AJR* 1984 ; 142(3): 535-38.